

implants

the international C.E. magazine of oral implantology

2²⁰¹²

_c.e. article

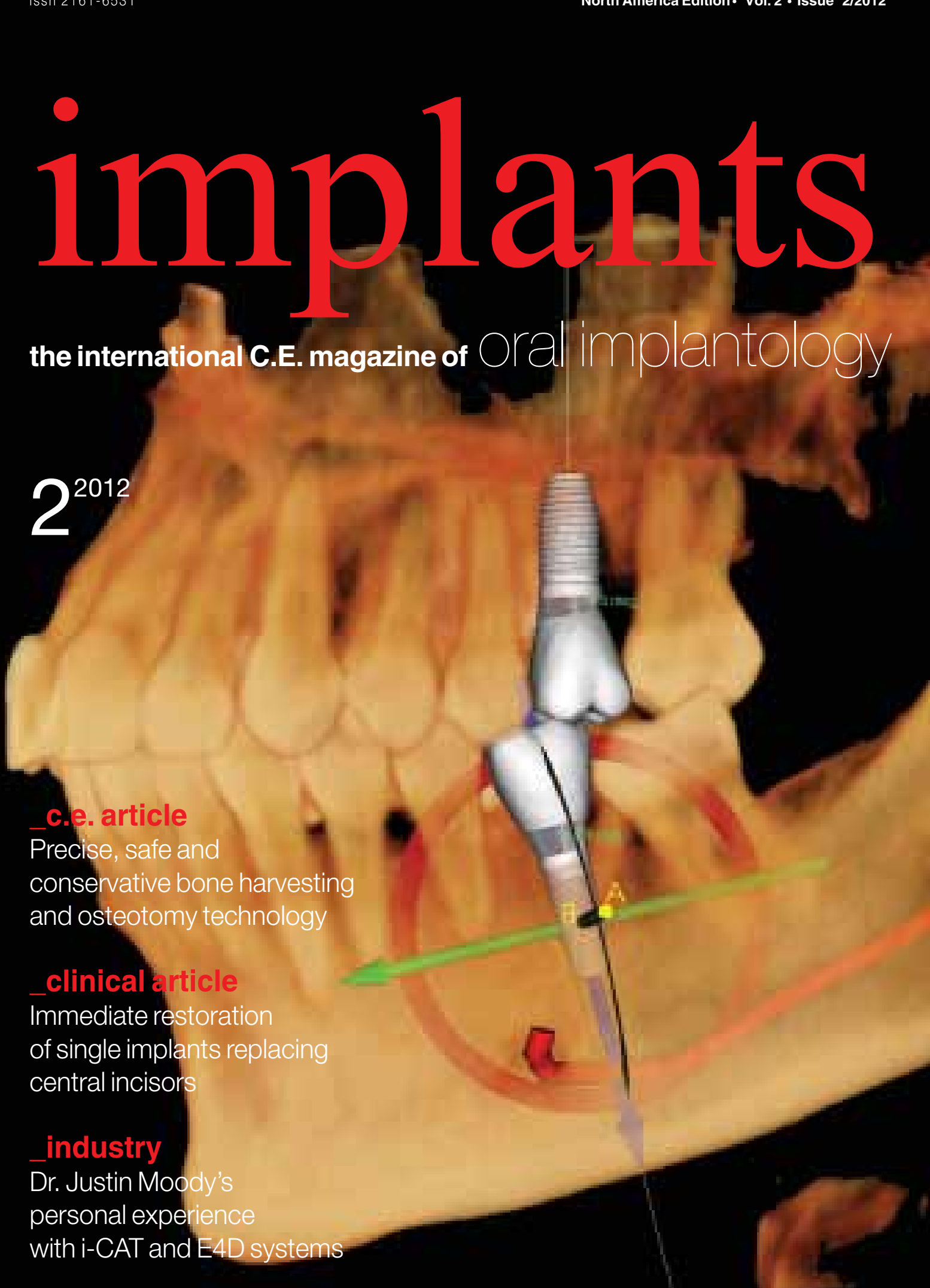Precise, safe and conservative bone harvesting and osteotomy technology

_clinical article

Immediate restoration of single implants replacing central incisors

_industry

Dr. Justin Moody's personal experience with i-CAT and E4D systems



Singh Guided Pin Surgery (GPS) Kit by MEISINGER

The Singh Guided Pin Surgery system (Meisinger USA) was developed out of the need for a simplified and conservative surgical system for implant dentistry and to minimize the need for non-autogenous-sourced hard-tissue grafting material. The eventual benefit would be a faster and safer method to create an ideal osteotomy while simultaneously collecting and harvesting substantial volumes of autogenous bone for grafting purposes.



Singh GPS Trephine Kit # SGPS

\$795.00

Meisinger

Meisinger USA, LLC

7442 South Tucson Way, Suite 130 • Centennial, Colorado 80112 • USA

Tel: +1 (303) 269-2400 • Fax: +1 (303) 269-5407

www.meisinger-usa.com • www.bone-management.com • info@meisinger-usa.com


Precise, safe and conservative bone harvesting and osteotomy technology

Authors Pankaj Singh, DDS, MD, DICOI, DABOI, FAAID, and Christine W. Chu, DDS

_c.e. credit
This article qualifies for C.E. credit. To take the C.E. quiz, log on to www.dtstudyclub.com. The quiz will be available on April 25.

Study: harvesting autogenous bone from the osteotomy site for minimally invasive implant placement using guided precision surgical trephines, and case report: osseous conservative crestal approach sinus lift

Figs. 1,2_GPS (Guided Precision Surgery, Meisinger) Trephines, side view. (Photos/Provided by Pankaj Singh, DDS, MD, DICOI, DABOI, FAAID, and Christine W. Chu, DDS)



designed and engineered Guided Precision Surgical (GPS) Trephines drills for the purpose of placing a dental implant, while simultaneously collecting substantial volume of autogenous bone that otherwise would have been discarded during the current osteotomy creation method using sequentially enlarging diameter spade drills.³ Included is a case report on how these drills can be used to prepare an osteotomy for a crestal approach sinus lift while simultaneously using the harvested bone for augmentation.

Materials and methods

The current method of creating a receptor site for a dental implant results in severe trauma (destruction and loss) to the host bone in the process. Depending on operator experience and bone type, it is very possible to oversize the osteotomy resulting in a non-optimum fit of the implant, which can cause failure due to non-integration.

Abstract

The specific aim of this project is to evaluate and substantiate the effectiveness and simplification of the osteotomy creation process using the newly

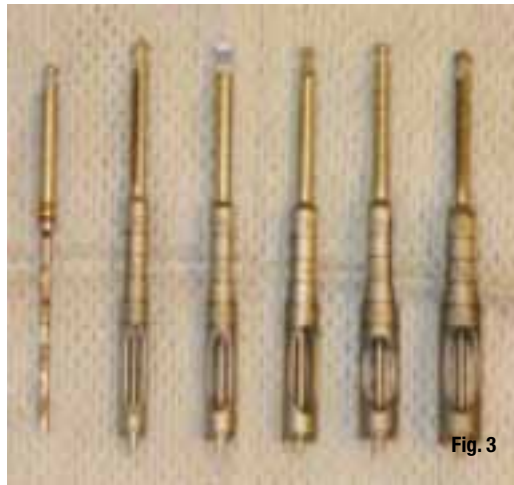

Fig. 3



Fig. 4

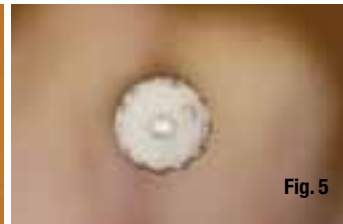

Fig. 5

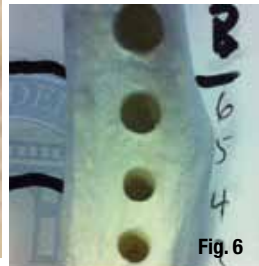


Fig. 6




Fig. 7



Fig. 8




Fig. 9

Fig. 3 Five trephine drills with outer diameters of 4.0 mm to 6.0 mm in 0.5 mm increments.

Fig. 4 Side view showing simulated bone captured during the drilling of the osteotomy.

Fig. 5 Aerial view showing captured bone surrounding the central guide pin.

Fig. 6 Crestal view of the osteotomy's created by the GPS drills.

Fig. 7 Side view of the GPS drills in the osteotomy sites.

Fig. 8 Crestal view of the side-by-side osteotomies created by the proprietary protocol on side A and GPS on side B

Fig. 9 Simulated bone cores removed from the GPS created osteotomies and measured for length.

Occasionally, there is need for hard-tissue augmentation of the implant; however, harvesting autogenous bone from a secondary site is not without significant morbidity and risk.

This study was designed to compare osteotomy creation and simultaneous bone harvesting using the newly introduced GPS (Guided Precision Surgery, Meisinger) Trephines (Figs. 1, 2) vs. traditional osteotomy using spade drills.

Use of the GPS Trephines: 1) simplifies and streamlines the surgical placement of implants, 2) minimizes trauma to the surgical site by using fewer instruments while simultaneously collecting vital autogenous, and 3) enables the harvesting of autogenous bone from the osteotomy site eliminating/decreasing the need for a secondary donor site or the use of alternative bone-grafting materials. Additionally, autogenous bone, considered to be the "Gold Standard"¹ in bone grafting, is invaluable in Guided Bone Regeneration² and further decreases the costs of bone-grafting materials.

The GPS Trephine system was developed out of the need for a simplified and conservative surgical system for implant dentistry and to minimize the need for non-autogenous sourced hard-tissue grafting material.⁴ The eventual benefit is a faster and safer method to create an ideal osteotomy while simultaneously collecting and harvesting substantial volumes of autogenous bone for grafting purpose.

The system allows the implant surgeon to accomplish the preparation of an osteotomy for the placement of an implant⁵ in only two steps, utilizing only two surgical drills, irrespective of the implant system and size of the implant being used.

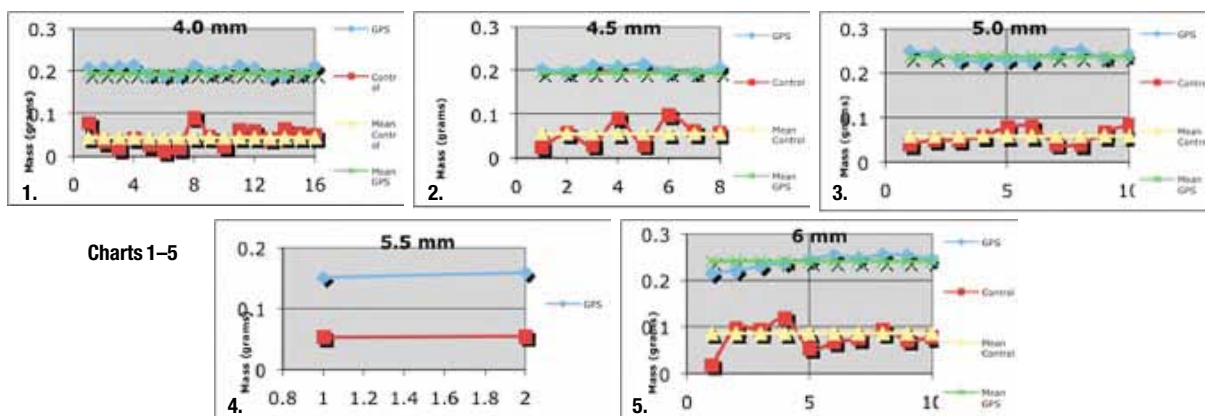
The system consists of a 1.3 mm pilot drill (two pilot drills are included as part of the system package, which function as guide and paralleling pins), five trephine drills with outer diameters of 4.0 mm to 6.0 mm in 0.5 mm increments (Fig. 3) and an auto-

clavable organizational bur block. The trephine allows for the capture of the bone block,⁶ 1 mm less in diameter (representing the internal diameter of the trephine) than the osteotomy (outer diameter of the trephine) (Figs. 4,5).

The trephines have a parallel walled 1.3 mm central guide pin that protrudes 1 mm past the cutting ends and is flat (non cutting). The unique aspect of this system is that the entire trephine with the central guide pin is fabricated in one piece using CAD/CAM manufacturing out of a single block of high strength metal. The parallel walls of the guide pin allow the trephine to advance along the shaft left from the pilot drill, preventing misdirection, and the extended flat-ended pin allows the trephine to advance to the depth defined by the pilot drill. Once "bottomed out," the trephine freely rotates around its central axis without risking extension of the osteotomy's depth or width.

This was a primary study using dense plastic simulated bone model mandibles, from which the data obtained would be used to submit for an IRB-approved human trial. Ten simulated bone mandibles were used to conduct a quantitative analysis of the amount of simulated bone salvaged during the osteotomy creation process, five different proprietary implant system drilling protocols were used and compared to newly introduced GPS Trephine system and drilling protocol for the same diameter implants.

Each mandible was designated a control (right) side and an experimental (left) side, and each implant system was allowed two mandibles with a minimum of four osteotomy sites per implant diameter. The drilling was carried out in sequence as per the pro-



Charts 1-5

proprietary implant system protocol⁷ on the control side and on the experimental side according to the GPS protocol (Fig. 6).

The five implant systems that were compared to GPS Trephines were: Screwline (Camlog, Henry Schein Inc.), Neoss, Osteotite – straight wall (BIOMET 3i), Screw-Vent (Zimmer Dental) and Replace Select (Nobel Biocare).⁸

On the control side, four osteotomies for each implant diameter per implant system were prepared to a depth of 10 mm as per the proprietary drilling sequence. On the experimental side, GPS protocol was used to prepare an osteotomy for the identical diameter implant of the system used on the control side (Fig. 7).

On the control side, the plastic bone from the flutes of the spade drills was collected per implant site and on the experimental side, the plastic bone collected from within the trephine or detached from the surrounding plastic mandible after the completion of the osteotomy for the implant was collected and weighted (Figs. 8, 9).

After implant planning and identification of the osteotomy sites as per usual manner and defined by standard of care:

Under copious external irrigation and at 750–1250 rpm depending on the type of bone⁹, the pilot drill is first advanced to a depth that measures im-

plant length + 1 mm, (e.g. for an 10 mm long implant, a 10 + 1 = 11 mm deep pilot hole will be created). An endodontic rubber stop can be used but is not necessary, as the pilot drill has laser cut markings at defined depths of 10 mm to 20 mm in increments of 2 mm to define that length.

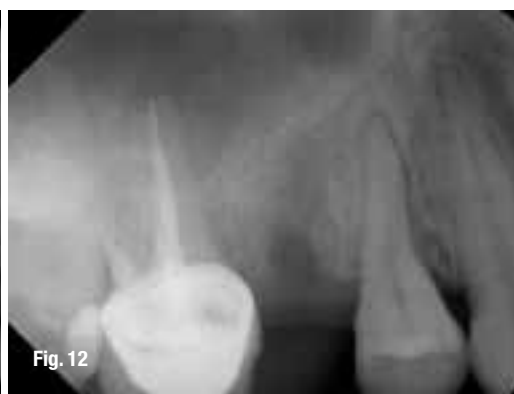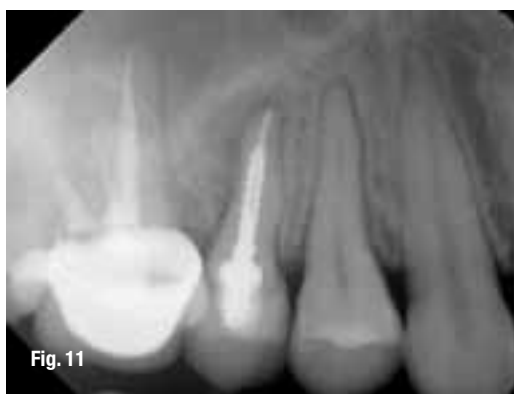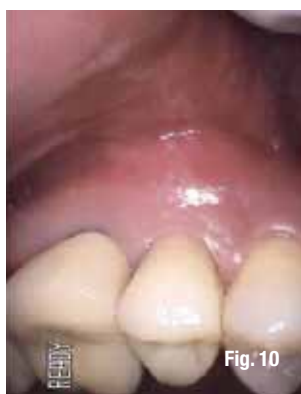A verification intraoral radiograph is taken with the pilot drill in place. If multiple side-by-side implants are being placed, then one pilot drill can be left in place to be used as a paralleling pin for the adjacent osteotomy.

A trephine is selected that has an outer diameter equal or no greater than 0.5 mm narrower than the diameter of the implant planned for the osteotomy, (e.g. for a 4 mm diameter implant, a 3.0/4.0 trephine will be needed, 3.0 mm is the internal core diameter of the trephine and will harvest a 3 mm diameter core of autogenous bone, 4.0 mm is the outer diameter of the trephine and leave a 4 mm cylindrical hole as the trephine only has end cutting edges and is not side cutting).

For a 4.8 mm diameter implant, a 3.5/4.5 trephine will be needed as the 4.5 outer core of the trephine is > 4.8-0.5 = 4.3 mm, this will allow a 3.5 mm core of bone to be harvested from the osteotomy site. Under copious external irrigation, the protruding pin of the trephine is introduced into the pilot hole and the cutting edges rested on the alveolar crest firmly.

Fig. 10 Class II mobility of tooth #4 and periodontal charting was WNL with no bleeding upon probing.

Figs. 11, 12 Radiographic examination of tooth #4.



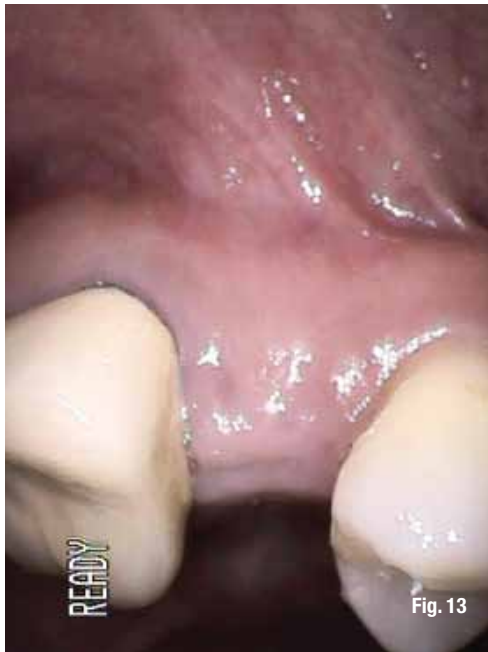

Fig. 13

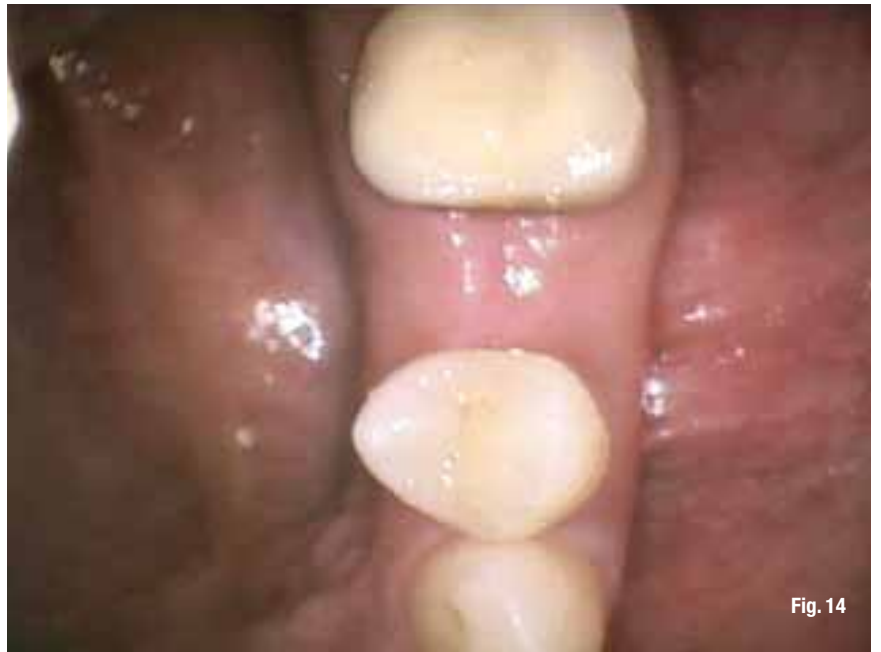

Fig. 14

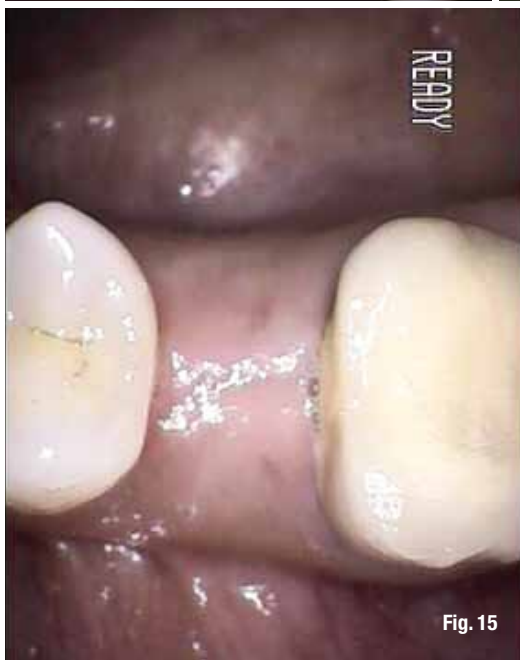

Fig. 15

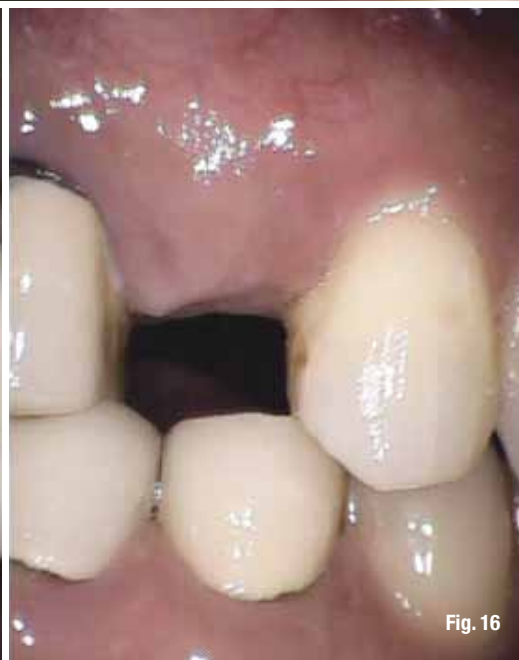

Fig. 16

Figs. 13–16 Soft-tissue healing and maturation had occurred.

The motor is set in a reverse mode at 500 rpm and activated for a few seconds until the end cutting teeth pattern has been created on the ridge. The motor is set back to forward setting and depending on the type of bone,¹⁰ under copious external irrigation at 750 – 1250 RPMs the trephine is introduced into the pilot hole and allowed to guide itself down the pilot hole until the trephine doesn't advance any farther (bottoms out) and either stalls or spins around its axis.

At this time, the trephine is reversed out of the osteotomy, and the bone trapped inside the trephine is slid out using the pointed end of a periosteal elevator. If the core of bone is left inside the oste-

otomy, attached only at the base, the pointed end of the periosteal elevator can be used to free it by luxation and elevated out using a pickup or college forceps. Upon extraction, the core is best stored in either sterile water or sterile normal saline solution. The core can be used as a block graft and retained using bone screws or can be morcellated for use as a particulate graft.¹⁰

The osteotomy is irrigated and visually inspected for integrity and the intended implant is inserted as per the insertion protocol defined by the implant manufacturer. It is always recommended that the few final turns be completed manually for tactile feedback as motorized insertion can apply exces-




Fig. 17

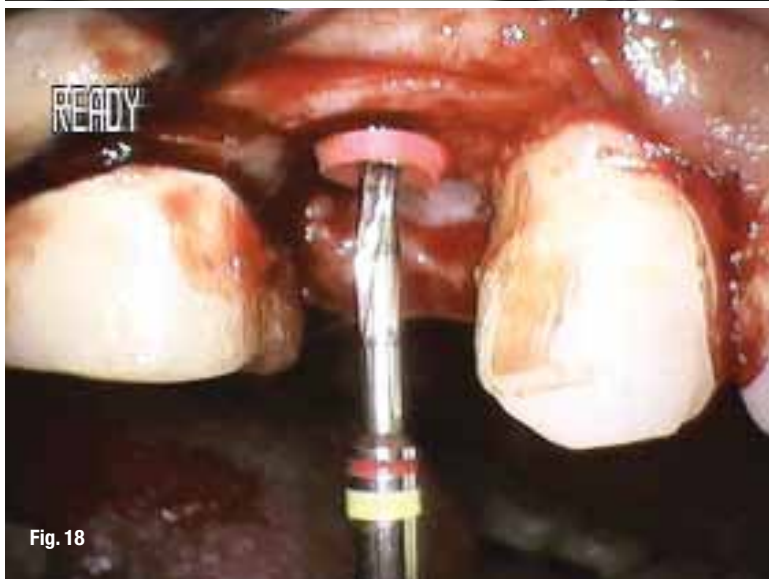

Fig. 18

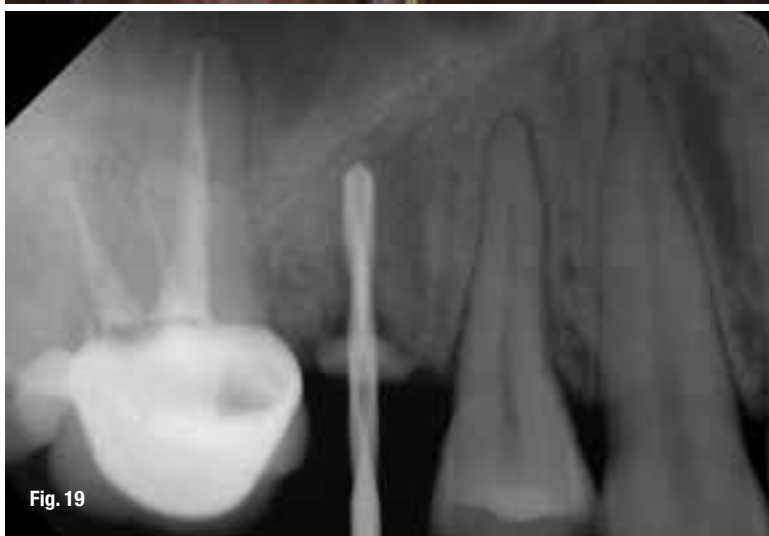

Fig. 19

Figs. 17–19 The midpoint of the edentulous space on the crest was determined and a 1.3 mm diameter pilot drill with an endodontic stop was introduced as per protocol set for the GPS trephines, to a depth of 7 mm from the crest of the ridge.

sive load on the osteotomy walls and may cause the implant to “spin.”

The GPS osteotomy creation protocol is the same for tapered and straight walled implants. For tapered implants, the apical discrepancy between the implant surface and the osteotomy walls will be treated by the body as a five-walled defect and fill in naturally without any need for grafting.

Results

Please see the five charts (Charts 1-5) for exact results of 4.0 mm through 6.0 mm.

Discussion

The 4.0 mm GPS's controls were 4.0 and 4.3 mm diameter osteotomies. The 4.5 mm GPS's controls were 4.5, 4.7 and 4.8 mm diameter osteotomies. The GPS protocol consistently harvested more bone than any of the spade drill systems used for control. The most consistent volume harvested was seen in the larger diameter GPS trephines. This was most likely due to the ease of removal of the core from the larger diameters than the smaller ones. Of all of the control systems used, the most amount of volume was collected from the Camlog system, while the least amount collected was from Nobel Biocare's.

Conclusion

From this study, it can be concluded that the GPS trephine system was not only able to create a perfectly sized osteotomy irrespective of the implant system it was compared with, it was also able to harvest bone in volume and weight more than two times that of the spade implant drills. Even though safety and speed were not part of the parameters being studied, it was observed that the osteotomies were created faster and with more precision using the GPS protocol.

Case report

A 35-year-old female patient presented for her regularly scheduled periodontal hygiene appointment and reported no change in her ASA1 medical status. She did, however, state that she had been experiencing occasional discomfort and swelling in the upper right premolar region and had been experiencing sensitivity to cold liquids as of the past several weeks, but she wanted to wait until her regularly scheduled appointment to have it examined.

Clinically, there was class II mobility of tooth #4 and periodontal charting was WNL with no bleeding upon probing (Fig. 10). There was tenderness to touch in the mucobuccal fold immediately overlaying tooth

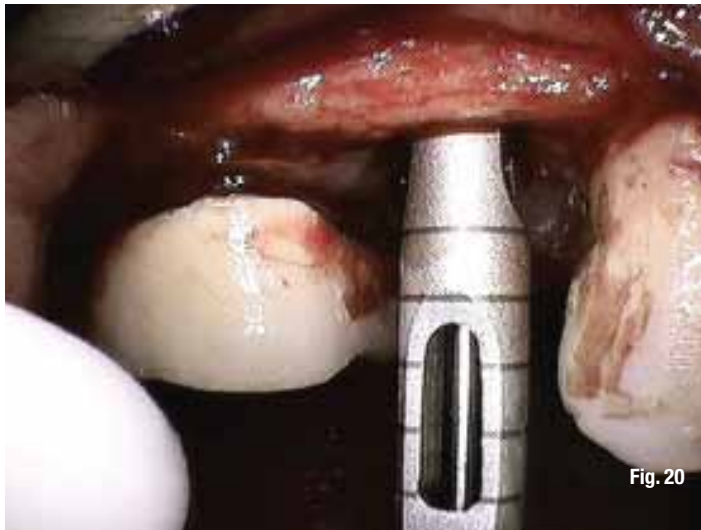


Fig. 20

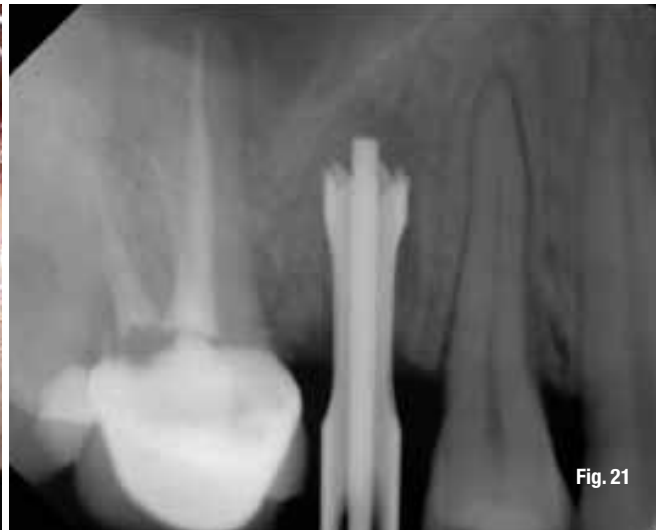

Fig. 21

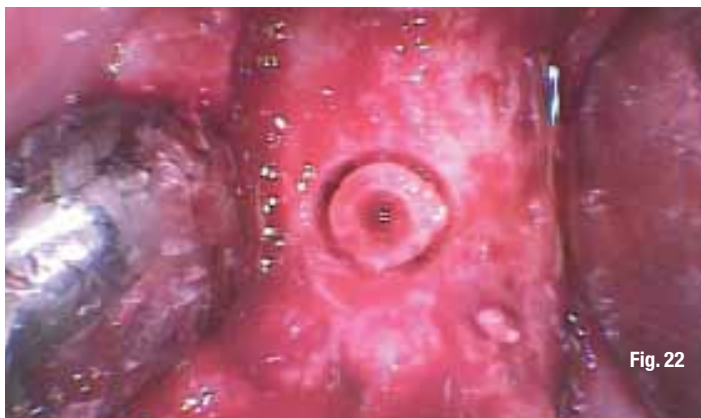


Fig. 22



Fig. 23

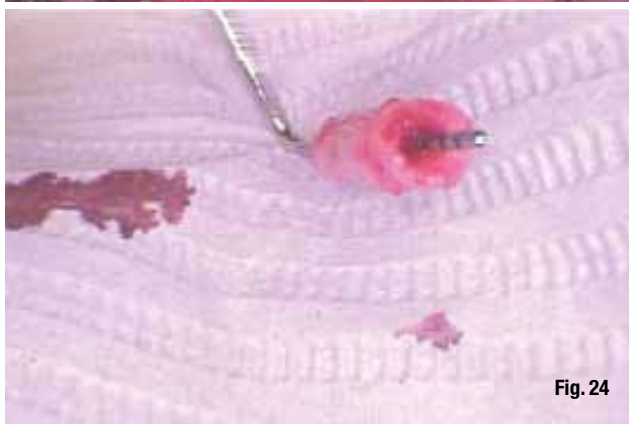

Fig. 24

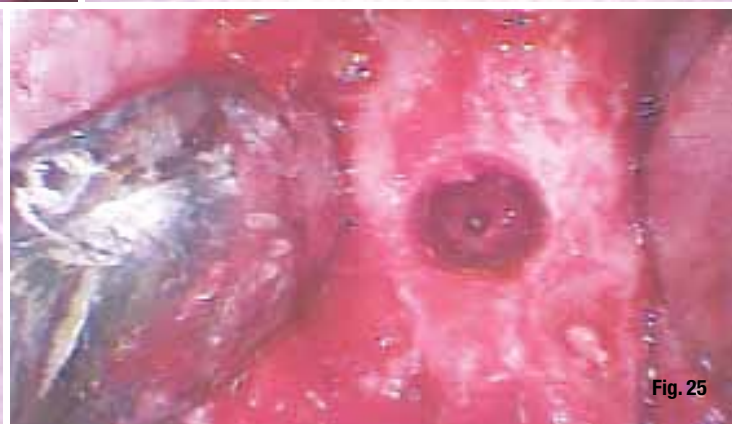

Fig. 25

#4. She admitted to not complying daily with the prescribed night guard as she suffers from sleep related bruxism (SB). There was tenderness to percussion to tooth #4, and upon radiographic examination (Fig. 11), it was concluded the tooth was non-salvageable. The treatment plan was to extract tooth #4 and allow socket and soft tissue to heal naturally and revisit the site in three months for implant placement (Fig. 12). At that time, enough sufficient soft-tissue healing and maturation had occurred (Figs. 13-16) to proceed with a crestal approach sinus lift and simultaneous implant placement.

The alveolar height was determined to be 8 mm from the base of the sinus floor, based on a calibrated PA radiograph (digital sensor, Sirona), and the plan was to place a 4 x 11.5 mm implant (Osteotite, BIOMET 3i).

At the time of implant placement surgery, 30 cc of whole blood was collected in 3 x 10 cc red top tubes and spun for PRGF.¹¹ Local anesthesia was administered for pain control, followed by a mid-crestal incision extending intrasulcular, one tooth proximal mesial and distal to implant site on both palatal and buccal aspects was made and flaps reflected to

Figs. 20, 21 A 4.0 mm GPS trephine was then used to create the osteotomy as per the GPS protocol.

Fig. 22 The core of bone still attached inside the osteotomy.

Figs. 23, 24 After the removal, the core of the bone was crushed into smaller pieces and stored in PRP.

Fig. 25 A 6 mm deep osteotomy with a 2 mm apical core of bone attached to the sinus floor.

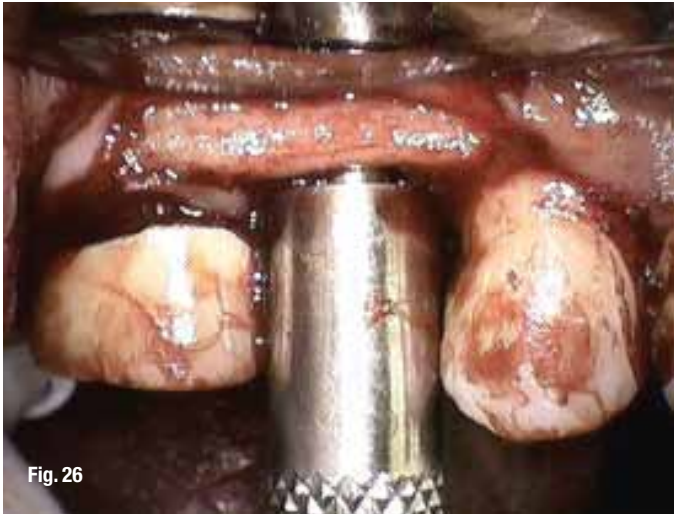


Fig. 26

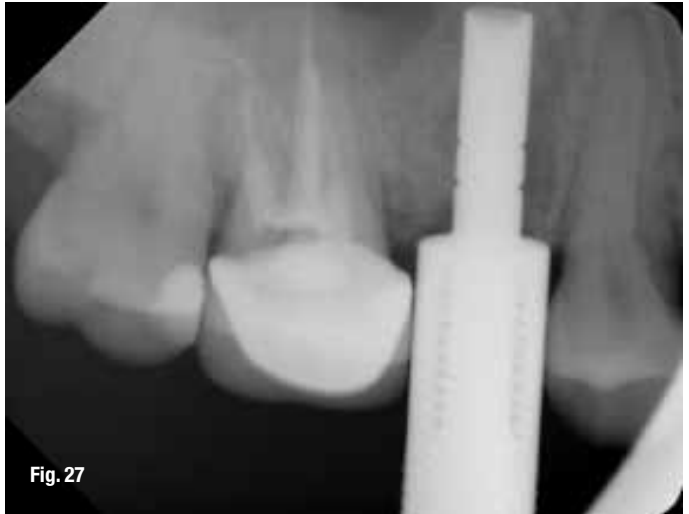

Fig. 27

Figs. 26, 27_A matching diameter osteotome.

Fig. 28_The floor of the sinus is infrafractured and pushed up.

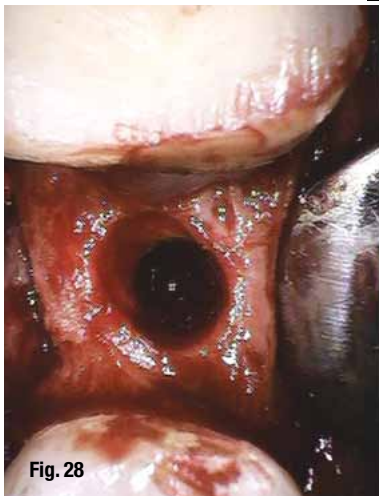


Fig. 28

Fig. 29_PrGF membrane.

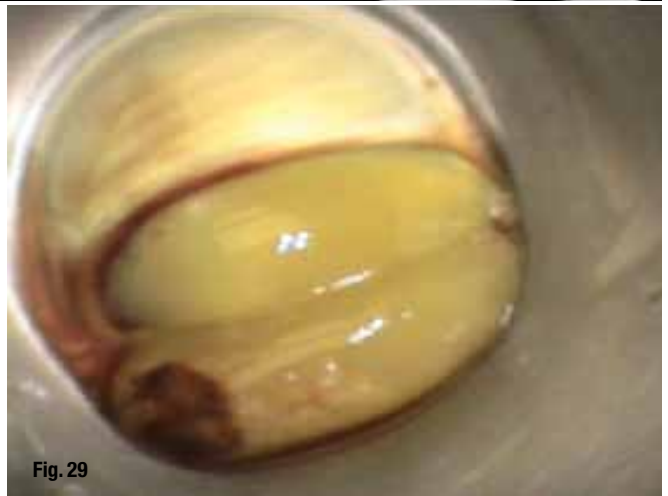

Fig. 29

Figs. 30, 31_The newly developed sinus floor.

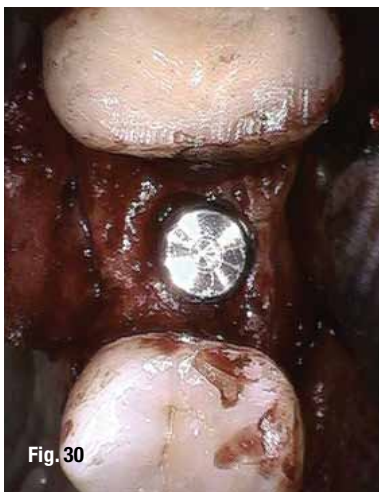


Fig. 30

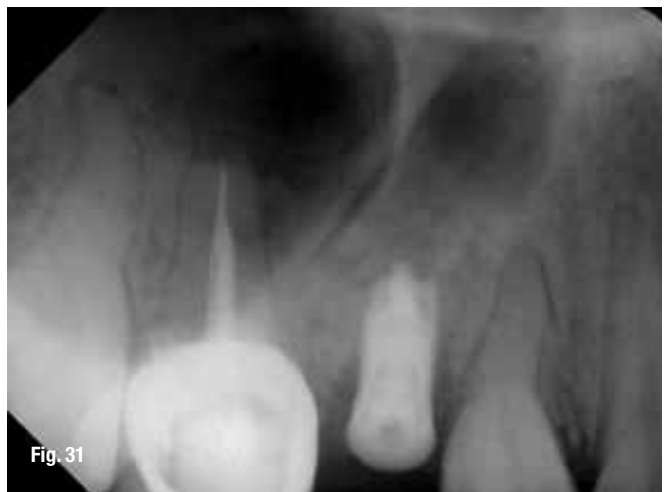

Fig. 31

expose the buccal and palatal bony walls including the crest.

The midpoint of the edentulous space on the crest was determined and a 1.3 mm diameter pilot drill with an endodontic stop was introduced as per protocol set for the GPS trephines, to a depth of 7 mm from the crest of the ridge (Figs. 17-19). A 4.0 mm GPS trephine was then used to create the osteotomy as

per the GPS protocol (Figs. 20, 21), leaving behind the core of bone still attached inside the osteotomy (Fig. 22) and, after the removal, the core of the bone was crushed into smaller pieces and stored in PRP (Fig. 23, 24), leaving a 6 mm deep osteotomy with a 2 mm apical core of bone attached to the sinus floor (Fig. 25).

Using a matching diameter osteotome (Figs. 26, 27), the floor of the sinus is infrafractured and pushed

up (Fig. 28) to accommodate the 11 mm deep implant and the integrity of the sinus verified. One PrGF membrane (Fig. 29) was introduced into the socket and pushed up against the sinus floor to protect it from the bone graft being introduced into the osteotomy socket and pushed apically into the newly developed sinus floor by the motorized insertion action of the implant (Fig. 30, 31). The osteotomy crestal access was sealed with an additional PrGF (Fig. 32) before flaps closure with Vicryl sutures (Ethicon).

Acknowledgement and disclaimer

Dr. Singh invented the "GPS Trephine System," which was developed with the assistance of engineers at Meisinger Instruments in Germany.

The authors wish to thank Dr. Burakoff, Dr. Stewart, and implant fellows and residents at North Shore, LIJ University Hospital for all of their hard work and commitment to the project.

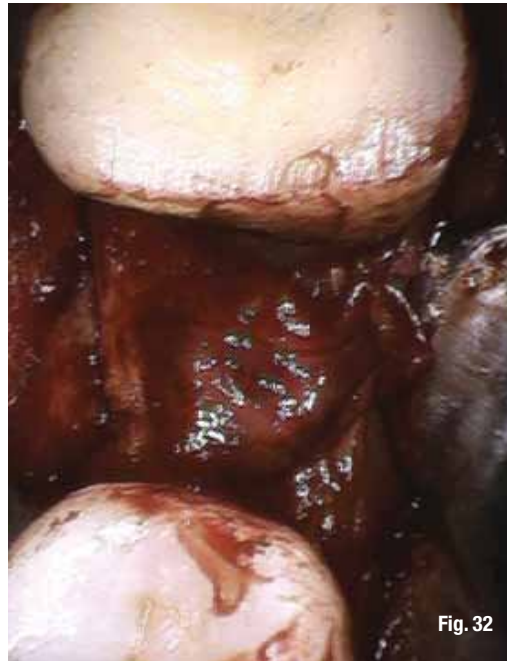

Fig. 32_ The osteotomy crestal access was sealed with an additional PrGF.

References

1. Becker W, Becker BE, Caffesse R. A comparison of demineralized freeze-dried bone and autologous bone to induce bone formation in human extraction sockets. *J Periodontology*. 1994; 65:1128-1133.
2. Bartee BK. Extraction site reconstruction for alveolar ridge preservation. Part 1: Rationale and material selection. *J of Oral Implantology*. 2001;27:187-193.
3. Singh P, Cranin AN. *Atlas of Oral Implantology*. 3rd ed. St. Louis, MO: Mosby; 2009.
4. Becktor J et al. The use of particulate bone grafts from the mandible for maxillary sinus floor augmentation before placement of surface modified implants: Results from bone grafting to delivery of the fixed prosthesis. *J Oral Maxillofacial Surg*. 2008; 66:780-786.
5. Garg AK. *Practical Approach to implant Dentistry*. 2nd ed. St. Louis, MO: Mosby; 2009.
6. Misch CE. *Keys to bone grafting and bone grafting materials*. Ln: *Contemporary Implant Dentistry*. 3rd ed. St. Louis, MO: Mosby; 2008.
7. Block MS. *Color Atlas of Dental Implant Surgery*. 3rd ed. St. Louis, MO: Mosby; 2009.
8. Taylor G. Intra-Oral bone grafting for dental Implant site preparation. *Dental Bulletin*; Vol.15 No.3 March 2010.
9. Marx R. Philosophy and particulars of autogenous bone grafting. *Oral & Maxillofacial Surg Clin N Am*. 1993; 5:5599-612.
10. Buser D, Dula K, Belser UC, et al. Localized ridge augmentation using GBR. II. Surgical procedure in the mandible. *Int J of Periodontics Restorative Dentistry*. 1995;15:10-29.
11. Singh, P. Use of Autologous Platelet Derived Growth Factors in Oral Surgery. *Implants Magazine*. 2012, 1:8-15.

about the authors

implants



Dr. Pankaj Singh received his doctor of dental surgery degree from New York University College of Dentistry and completed his residency and fellowship in dental/oral surgery and dental/oral implantology at Brookdale Hospital Medical Center in New York. He received an advanced certificate in IV anesthesia from Montifiore Hospital and Albert Einstein School of Medicine. He is an

attending and research scientist in the Department of Dental Medicine and Oral Surgery at LIJ/NS University Hospital in Long Island, N.Y., as well as an associate professor in the International Dental

Program Department at NYU College of Dentistry. For more information, visit www.archdental.com.

Dr. Christine Chu is a general dentist, with an emphasis on cosmetic and restorative dentistry. She received her bachelor of science in biochemistry from The State University of New York at Stony Brook and her doctor of dental surgery degree from the State University of New York at Buffalo. She completed her post-doctoral training in a general practice residency at the North Shore-Long Island Jewish Health System.

